



**CONGENITAL AND JUVENILE HYPOTHYROIDISM  
DUE TO THYROID DYSGENESIS**

*GERALDO A. MEDEIROS NETO, L. M. DE ASSIS, WILLIAM NICOLAU, A. S. COELHO NETO, W. BLOISE, W. LUTHOLD, J. L. MONTENEGRO and RÔMULO R. PIERONI*

**PUBLICAÇÃO IEA N.º**

Dezembro — 1965

**113**



**INSTITUTO DE ENERGIA ATÔMICA**

Caixa Postal 11049 (Pinheiros)  
CIDADE UNIVERSITÁRIA "ARMANDO DE SALLES OLIVEIRA"  
SAO PAULO — BRASIL

CONGENITAL AND JUVENILE HYPOTHYROIDISM

DUE TO THYROID DYSGENESIS

Geraldo A. Medeiros Neto<sup>1</sup>, L.M. de Assis, William Nicolau,  
A.S. Coelho Neto, W. Bloise, W. Luthold, J.L. Montenegro  
and Rômulo R. Pieroni

Divisão de Radiobiologia  
Instituto de Energia Atômica  
São Paulo - Brasil

Publicação IEA nº 113

Dezembro - 1965

Comissão Nacional de Energia Nuclear

Presidente: Prof. Luiz Cintra do Prado

Universidade de São Paulo

Reitor: Prof. Luiz Antonio da Gama e Silva

Instituto de Energia Atômica

Diretor: Prof. Rômulo Ribeiro Pieroni

Conselho Técnico-Científico do IEA

Prof. Hélio Lourenço de Oliveira	)	pela USP
Prof. Walter Borzani		
Prof. Rui Ribeiro Franco	)	pela CNEN
Prof. Theodoreto H.I. de Arruda Souto		

Divisões Didático-Científicas:

Div. de Física Nuclear: Prof. Marcello D.S. Santos

Div. de Engenharia Nuclear: Pedro Bento de Camargo

Div. de Ensino e Formação: Prof. Luiz Cintra do Prado  
(Licenciado)

Div. de Radioquímica: Prof. Fausto Walter de Lima

Div. de Radiobiologia: Prof. Rômulo Ribeiro Pieroni

Div. de Metalurgia Nuclear: Prof. Tharcísio D.S. Santos

Div. de Engenharia Química: Prof. Kazimierz J. Brill

Div. de Física de Reatores:

## CONGENITAL AND JUVENILE HYPOTHYROIDISM

### DUE TO THYROID DYSGENESIS

Geraldo A. Medeiros Neto<sup>1</sup>, L.M. de Assis, William Nicolau,  
A.S. Coelho Neto, W. Bloise, W. Luthold, J.L. Montenegro  
and Rômulo R. Pieroni  
São Paulo - Brazil

RESUMO: Treze pacientes com tecido tireoideano ectópico foram seguidos durante três anos. Distribuem-se nos quatro grupos seguintes:

Grupo I (4 casos) - Quadro clínico completo de hipotireoidismo congênito, com acentuado retardo mental.

Grupo II (5 casos) - Desenvolveram hipotireoidismo em diferentes idades, entre 1 e 5 anos; quadro clínico menos severo e grau leve de retardo mental.

Grupo III (2 casos) - O hipotireoidismo iniciou-se na adolescência com diferenciação sexual normal, mas com parada de crescimento.

Grupo IV (2 casos) - Adultos com eutireoidismo e massa tumoral palpável na região sub-lingual. Esta tura bem abaixo da média.

Não foram encontrados sinais de alterações neuromusculares nem de surdes e afasia. Não foram constatados incidência familiar de bócio e consanguinidade; dois casos, no entanto, foram localizados numa mesma família.

Com exceção do grupo IV, todos os pacientes exibiam hipercolesterolemia, PBI baixo e captação de radioiôdo em níveis inferiores ao normal. A idade óssea revelou-se atrasada, com a presença de quatro casos de disgenesia epifisária nos grupos I e II. O cintilograma da região cervical anterior mostrou, em todos os casos, pequena formação, com área de projeção arredondada, captante, situada na região sub-lingual. Não foi possível correlacionar o quadro clínico com as dimensões presumíveis do tecido ectópico.

Duas e seis horas após o teste de estímulo com TSH exógeno, observou-se discreto aumento no PBI dos pacientes dos grupos I e II, mas não nos grupos III e IV. O fato pode sugerir graus diversos de estímulo pelo TSH endógeno, nestes grupos.

Em oito pares, mãe-filho portador de tecido ectópico, foram negativos os testes para detecção de anticorpos antitireoglobulina circulante, o que torna pouco provável a possibilidade de haver fator imunitário na etiologia do tecido ectópico.

Na maioria dos pacientes o tecido ectópico mostrou-se capaz de sintetizar e lançar na circulação, tri-iôdo-tironina e tiroxina, cromatograficamente identificados e que podem ser responsabilizados pelo grau variável de desenvolvimento post-natal.

\*\*\*\*\*

## Congenital and Juvenile Hypothyroidism Due to Thyroid Dysgenesis

Geraldo A. Medeiros-Neto,<sup>1</sup> L. M. de Assis, William Nicolau, A. S. Coelho-Neto, W. Bloise, W. Luthold, J. L. Montenegro and R. R. Pieroni<sup>2</sup>

*Sao Paulo, Brazil*

Following the initial description of an ectopic thyroid by Verneuil, (1) it remained only as an anatomical curiosity for many years.

Hunt (2) described dysphagia and obstruction of the upper larynx caused by a lingual thyroid and suggested the clinical importance of this entity. Montgomery (3) has reviewed most of the reported cases, and observed that surgical ablation of the ectopic tissue was followed by hypothyroidism (4).

With the use of radioiodine in the diagnosis of thyroid disease, more than 300 cases of ectopic tissue had been described by 1956, most of them having clinical symptoms related to impaired respiration or swallowing (5).

The first functional approach to the problem of ectopic thyroid tissue was made by McGirr and Hutchinson (6), who reported two cases associated with myxedema and cretinism. A tracer dose of radioiodine revealed that most of the labeled iodide was present in the base of the tongue. The cause of myxedema in these patients was the failure of the ectopic thyroid to maintain physiological levels of thyroid hormones in the plasma.

Kellershohn and his associates (7) reported that 60 per cent of 23 children with congenital hypothyroidism had evidence of ectopic thyroid. Other reports (8-9) seem to confirm an elevated incidence of this anomaly in children or adolescents with hypothyroidism.

The present paper reports the clinical and laboratory observations and the progress of thirteen patients with thyroid remnants studied at the Hospital das Clinicas, University of Sao Paulo Medical School in cooperation with the Atomic Energy Institute.

<sup>1</sup>Fellow in Radiological Research, James Picker Foundation.

<sup>2</sup>From the First Medical Clinics, Hospital das Clinicas da Universidade de Sao Paulo and Instituto de Energia Atomica, Sao Paulo, Brazil.

## MATERIALS AND METHODS

Fifteen children and young adults were examined for hypothyroidism: in two a diagnosis of complete thyroid agenesis was made. In the remaining thirteen cases a small thyroid remnant was found in a variable position in the upper part of the neck. Two cases occurred in the same family. Eight females and five males, ranging in age from 15 months to 46 years are studied in this report.

The iodide uptake was performed according to a previously reported standardized technique (10). Serum cholesterol was measured by the method of Navajas (11) and the serum protein bound iodine (PBI) by a modification of the method of Barker (12).

The bone age was estimated by Todd standards fixing x-rays films of wrists, elbows, hip and knees in most patients. All patients were submitted to a thyroid stimulating hormone (TSH) stimulation test. Our standard technique uses 5 units of TSH<sup>1</sup> intramuscularly in two consecutive days. PBI determinations were performed before the TSH injection and several times after the first and second dose of TSH, during a 96 hour period. Thus, it was possible to compare the early and late effect of TSH on the thyroid remnant.

In eight cases both maternal and patient blood were obtained for anti-thyroid antibodies determination. Gel diffusion in agar and tanned red cell agglutination were performed according to the methods of Strauss *et al* (13).

## RESULTS

*Clinical degree of hypothyroidism*—Because of the great variability of the clinical findings, the patients were divided into four groups according to the degree of hypothyroidism (Table I):

*Group one:* (4 cases) presented a clinical picture of severe congenital hypothyroidism with marked mental retardation (Fig. 1)

*Group two:* (5 cases) developed hypothyroidism at different ages between 1-5 years. These patients exhibited less severe physical and mental retardation (Fig. 2)

*Group three:* (2 cases) the hypothyroidism began at adolescence with normal sexual differentiation and mental picture but stunted growth (Fig. 3)

*Group four:* (2 cases) Euthyroid adults with a palpable tumor at the sublingual region and short stature (Figs. 4, 5).

Patients in groups one and two have most of the findings described as typical infantile hypothyroidism; macroglossia, anemia, coarse, cool and dry skin, brittle hair and protuberant belly with umbilical hernac.

In group one all patients look like cretins and have a body habitus of infantile proportions with a large head and extremities short in proportion to the trunk. In group two, however, the clinical picture of cretinism was much less striking. The body proportions and the facies (Fig. 2) could be considered almost normal. Peripheral signs were less prominent. Symptoms suggestive of hypo-

<sup>1</sup>Supplied as Ambion by Organon Co. (Holland).

thyroidism, such as constipation, poor appetite and decreased physical activity were much less pronounced than group one.

A common feature among all groups was stunted growth. Even in the euthyroid subjects of group 4, the final height achieved was well below the average height for the normal adult population (Figs. 3-5).

The weight was usually below the 5-95 per cent limit for each age group. One of the patients in group three (N.E.S.) had marked obesity.

In patients belonging to groups one and two, considerable delay in bone age was observed (Table I). Usually bone age was close to height age, but in four cases the former was more retarded than the latter. In the two cases of group three, bone age was considered in the normal range for preadolescents. Thus, in these patients, skeletal maturation progressed satisfactorily until puberty.

Epiphyseal dysgenesis, especially at the head of the femur, was present in four cases, two from group one and two from group two.

At the time of evaluation most of the patients of the first two groups showed marked mental retardation, although no tests were performed to establish quantitative differences between the patients.

None of the patients, with hypothyroidism of the normal thyroid function have deaf-mutism or the neuromotor impairment described in association with endemic cretinism (14).

*Laboratory Data*—The laboratory findings are in Table II. Serum cholesterol was above normal limits in two of the four patients in group one, and in four of the five patients in group two. All four patients in groups three and four had normal levels of cholesterol. Serum inorganic phosphorus levels were within the normal range for children and adolescents in groups one and two, but were high

TABLE I  
CLINICAL FINDINGS IN THIRTEEN PATIENTS WITH THYROID DYSGENESIS

	<i>Group One</i> (4 patients)	<i>Group Two</i> (5 patients)	<i>Group Three</i> (2 patients)	<i>Group Four</i> (2 patients)
Cretin facies	All	None	None	No
Anemia	All	All	None	No
Coarse, dry skin	All	All	All	No
Macroglossia	All	1	None	No
Umbilical hernia	All	2	None	No
Constipation	All	4	All	No
Prolonged icterus neon	All	None	None	No
Chronological age*	4.6-12	2.5-12	17.5-12	37.3-12
Height age*	3.9-12	3.1-12	13.6-12	12.3-12
Bone age*	2.4-12	1.1-12	13.3-12	Normal
Epiphyseal dysgenesis	2	2	None	None

\*Means, Years



compared to values that were reported for hypothyroid children (15). The PBI estimations were below normal in group three and normal in the two patients of group four.

The radioactive iodide ( $^{131}\text{I}$ ) uptake was below our standards of normality (2 hours  $12.5 \pm 6.5\%$  and 24 hours  $33.0 \pm 12.50\%$  of the administered dose) (10) for groups one, two and three, but was within normal range in patients of group four.

The most important test for the diagnosis of the ectopic thyroid tissue was the scanning of the sublingual region 24 hours after the tracers doses of radioactive iodine. Typical scans are shown in Fig. 6. In all cases, detectable radioactivity was present in the area near the base of the tongue. An attempt was made to measure the area of ectopic thyroid outlined by the scan in order to estimate the weight of the tissue (7). In most cases, it was calculated to be less than 5.0 gm but in the two case of group four, JAP and EML, it was calculated to be 9.0 and 15.0 gms, respectively. No attempt to classify the patients by either

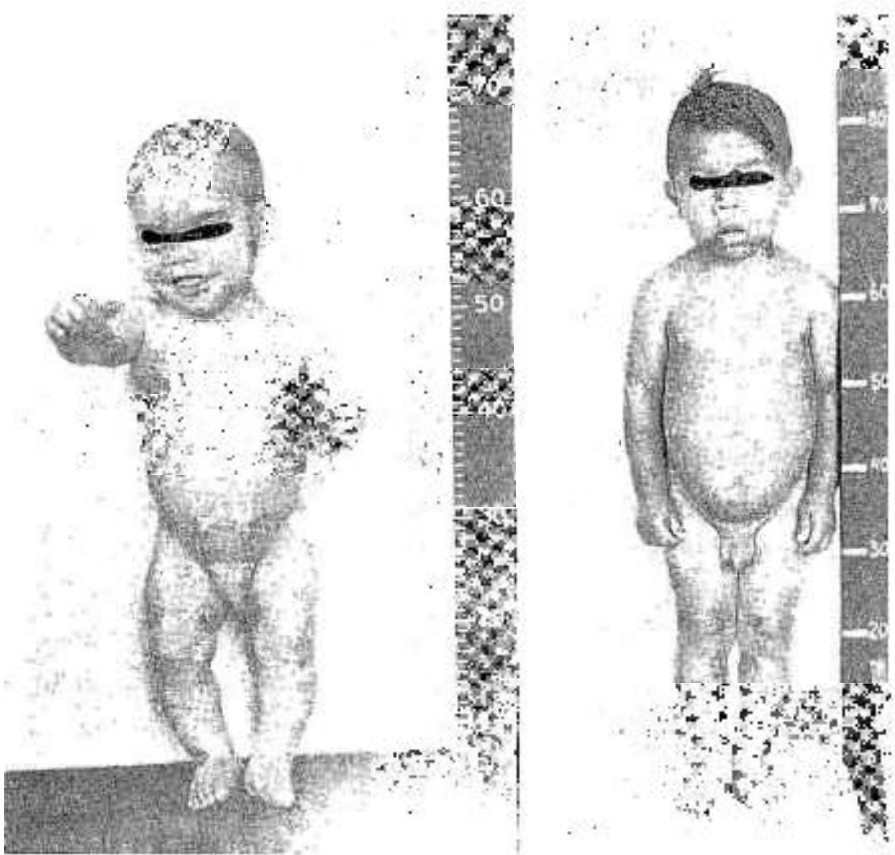


Fig. 1. Two patients of Group one: Note cretin facies, protuberant belly with umbilical hernia, large head and the shortness of the extremities short in proportion to the trunk. The boy on the right had a normal development until the first year of age. The boy on the left has congenital hypothyroidism.

TABLE II  
LABORATORY DATA OF THIRTEEN PATIENTS WITH EUTHYROID THYROID

Case No.	Group A			Group B			Group C			Group D			
	SLO	WBC <sup>a</sup>	D.I.P.	RAMF	S.M.Z.	U <sub>75</sub>	CTS	R.S.V.	R.S.V.	S.S.S.	S.S.S.	SAP	W.H.H.
Cholesterol (Mg 100 ml)	402	--	273	188	364	315	307	286	315	249	173	221	255
Inorganic phosphorus (Mg 100 ml)	5.3	--	4.1	5.8	3.1	4.8	5.0	6.2	5.3	5.5	3.8	4.0	4.8
PBI $\mu$ g 100 ml	0.7	1.1	1.4	0.8	1.2	1.5	1.1	1.8	2.0	2.5	3.6	5.1	6.5
Radioactive iodine	2.0	2.0	5.5	0.5	3.0	3.5	0.1	5.0	3.0	7.0	5.5	12.0	10.0
24 hrs	4.5	8.5	9.8	1.5	5.5	8.0	3.0	7.5	2.5	7.5	15.0	29.0	45.0
48 hrs	4.0	6.0	6.0	1.5	2.0	0.5	1.0	7.0	3.5	10.5	14.0	24.0	40.0

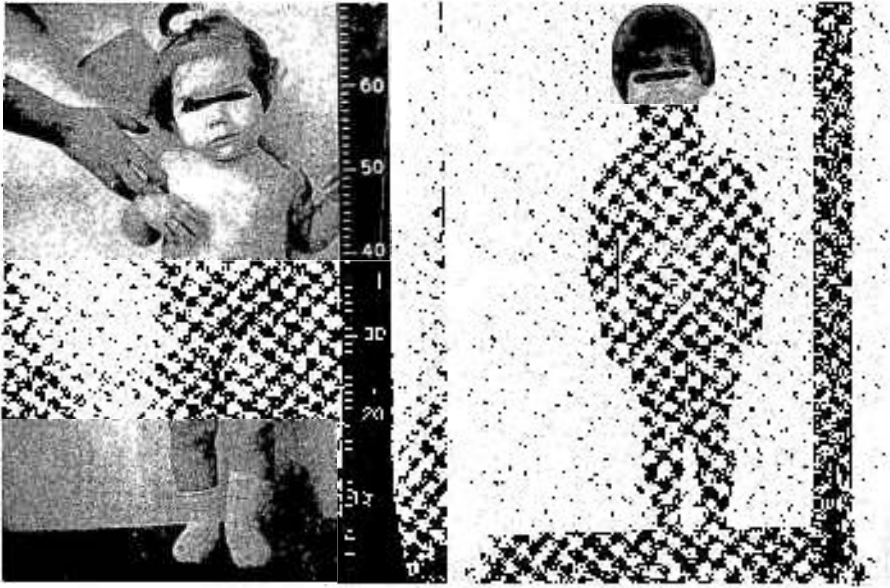


Fig. 2. Two patients from Group two. Note the few signs of classical congenital hypothyroidism. Body proportions are close to normal, although definite stunted growth is observed.

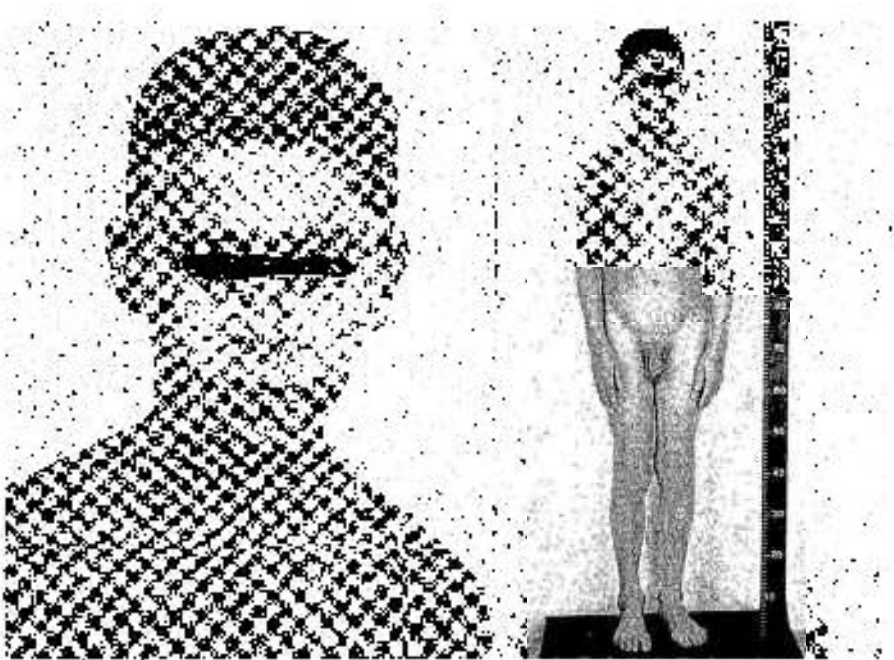


Fig. 3. One of the patients of Group three. Note normal body proportions, an early adolescence sexual development with very few signs of hypothyroidism but stunted growth.

the estimate weight or relative position in the upper neck was made. Little variation in size, if any, or in position was observed among groups one, two and three. However, the two patients in a group A (JAP and EML.) had a larger thyroid remnant than the other patients (Fig. 6). Thus, although definite clinical differences between groups were present, minimal variation in size, weight or position of the ectopic tissue were observed. This may suggest that the mass of the thyroid tissue, as judged by the thyroid scan, is only of relatively prognostic value.

Tests for antithyroid antibodies were done in eight patients and in their respective mothers. All children belonging to groups one and two were hypothyroid. No visible or palpable goiter or clinical symptoms of thyroid disease were found in the seven mothers examined, although no tests of thyroid function were performed.<sup>1</sup> In all eight pairs, mother-child tests for precipitins (gel diffusion in agar) or for antithyroglobulin agglutinins (tanned red cell agglutination) were repeatedly negative.

*The thyrotropic hormone (TSH) test*—In groups one and two, a significant rise in the serum PBI was observed at two and six hours following the injection of 5 units of TSH. Even with a second dose of TSH after 24 hours, no further increase in PBI was observed. The rise of PBI at two and six hours is significant at a level of, respectively,  $P < .01$  and  $P < .05$ . No significant modification of PBI was observed in the patients of groups of 3 and 4, either after one or two injections of TSH (Table III).

#### DISCUSSION

Few endocrine glands have shown so much variation in shape and position as has the thyroid gland. Aberrant thyroid tissue has been found from the base of the tongue to the diaphragm (16). This may be related to the embryological development of thyroid tissue.

Thyroid tissue in the human fetus has been found as early as the 17th day. The proliferative endoderm makes a depression on the bottom of the pharynx, where it comes into close contact with the endothelium of the newly formed myocardium. This median portion of the thyroid tissue assumes the shape of a pouch that is closely related to the aortic sac. As soon as the primitive myocardium is disassociated from the pharynx, the thyroid assumes the shape of a vesicle with a narrow connection with the pharynx (16). This thyroid vesicle becomes more differentiated and is dislocated from the primitive point to a position progressively more downward following the descent of the primitive heart. Thus, the embryological heart exerts a definite mechanical influence on the formation of the thyroid and its location in the neck.

Little is known about the factors that influence the critical steps which take place during the descent of the primitive thyroid and heart, and one is tempted to believe that they may play a definite, although unknown, role in the etiology of ectopic thyroid. Immunologic and genetic factors have been considered of some importance.

<sup>1</sup>In only one mother was a goiter found; this later proved to have a high uptake of radioiodide (65% in 24 hours) and had a negative suppression test. It is noteworthy that this woman was the mother of the two siblings with ectopic thyroid.

It has been suggested that maternal thyroid antibodies could directly or indirectly play a role in causing congenital hypothyroidism. Chandler and his associates (17) demonstrated that of 121 mothers, whose children were supposedly athyreotic cretins, 24.8 per cent had detectable antibodies. More than 1/2 of the mothers, however, have negative tests for autoimmunity. In our series, no positive test for antithyroid antibodies was found in eight mothers or their children with ectopic tissue. Thus, it seems unlikely that autoimmunity has a definite and consistent influence in causing thyroid dysgenesis, although participation cannot be entirely excluded.

It has been suggested (18) that congenital cretinism may result from a genetic defect of both thyroid tissue and the central nervous system. An elevated incidence of skull abnormality by x-ray, clinical signs of neuromuscular impairment and electroencephalographic disturbances supported this theory. Clements (19) believes that genetic factor must be present in cases of sporadic or endemic cretinism, noting that this condition is more common in small, isolated geographical areas where inbreeding is quite common, favoring accumulation of harmful genes.

No signs of neuromuscular impairment or abnormalities in the skull films were observed in our patients. Furthermore, although two cases were detected in the same family, no positive familial evidence of goiter was found in other cases. A genetic chart was kept for most of the cases studied and no inbreedings were detected. It seems unlikely that a recessive accumulated gene may act in these cases, although only a more careful retrospective and planned study could answer this point.

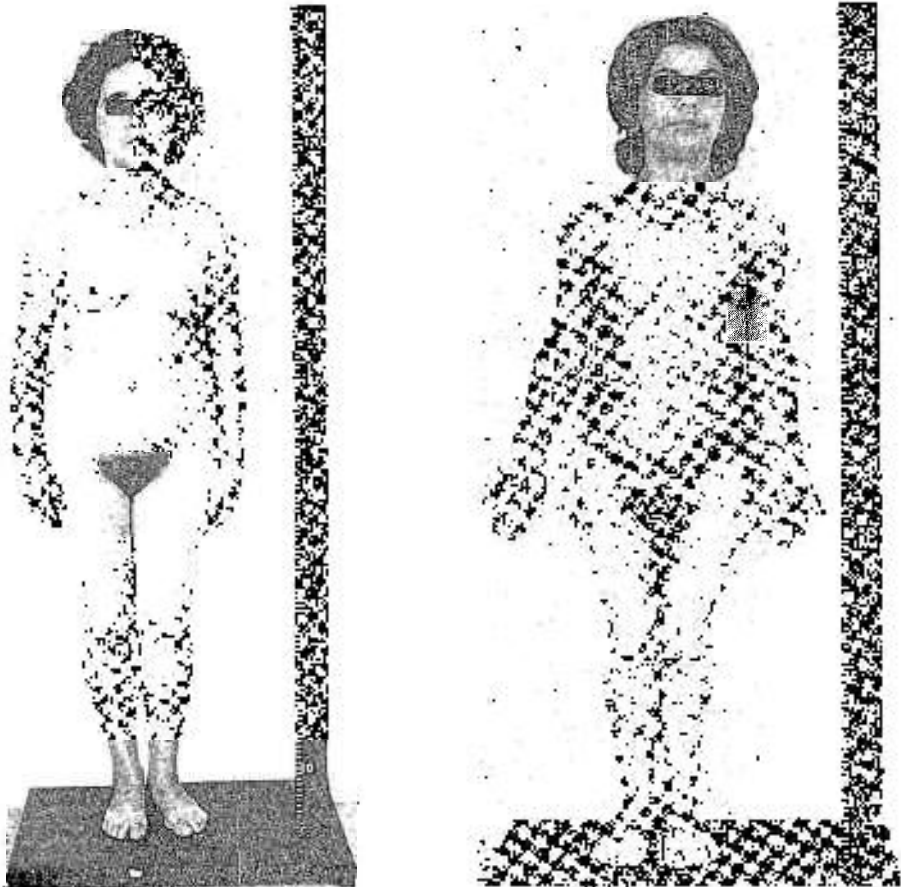
The extreme variation of the clinical picture is remarkable in thyroid dysgenesis. Stanbury (20) states that cretinism is mainly due to thyroid insufficiency during the embryological period. Normal thyroid function observed in the adult life of some of these patients could be attributed to a greater supply of iodide than during fetal life.

TABLE III  
SERUM PBI OF PATIENTS WITH ECTOPIC THYROID AS AFFECTED BY TSH  
ADMINISTRATION  
( $\mu\text{G}$  PER 100 ML.)

	<i>Control</i>	<i>2 Hours</i>	<i>6 Hours</i>	<i>24 Hours</i>	<i>48 Hours</i>
Groups 1 and 2 (mean and S.D.)	0.98 $\pm .42$	1.93 $\pm .69$	1.84 $\pm .65$	1.77 $\pm .57$	1.78 $\pm 1.6$
P	--	< .01	< .05	< .01	> 0.1
Groups 3 and 4 (mean and S.D.)	4.37 $\pm 1.66$	4.42 $\pm 1.60$	4.45 $\pm 1.63$	4.55 $\pm 1.63$	4.27 $\pm 1.75$
P	--	> .8	> .8	> .7	> .8

Lobo and his associates (14) recently studied 26 cretins in an endemic region of central Brazil. Only two could be classified as hypothyroid and 10 were deaf-mutes. Signs of neuromuscular abnormalities and pathological alterations on EEG were also reported. These authors comment that if thyroid deficiency is the main cause of endemic cretinism, these neurological signs, including deaf-mutism, should be observed more frequently in the supposedly athyreotic cretins, or in patients with a complete block of the hormonal synthesis by means of one of the inborn metabolic errors of thyroid hormones synthesis. It is possible that placental transfer of thyroid hormones could prevent major neurological signs in these cases, but not congenital hypothyroidism (14).

In most cretins that have been considered supposedly athyreotic, a thyroid remnant could be responsible for a small production of thyroid hormone during the embryonal life. Our own experience (only two of thirteen children were athyreotic) and reports from several different groups (7-9) seems to agree that athyreosis is a rare condition and studies with radioactive iodide can detect



Figs. 4, 5. The two adults in Group four showed normal body proportions and sexual maturity. No signs of hypothyroidism but a very short stature is observed.

ectopic thyroid tissue in most of the children with congenital hypothyroidism.

An argument can be put forward that the thyroid remnant would provide for some thyroid hormone production during fetal life maintained for a variable period of postnatal life. The thyroid hormone produced could possibly prevent the appearance of neurological disorders that have been associated with endemic cretinism, but have not been found in congenital hypothyroidism. The remarkable variation in the degree of hypothyroidism found in our cases supports this view. The thyroid remnant in some cases provides for a close to euthyroid state until adolescence and in two cases, until adult life. A relative thyroid insufficiency, however, might be present during all the postnatal life because, in any case, these patients have achieved a normal adult height.

Whatever the cause for thyroid dysgenesis, it does not seem to act after postnatal life. The thyroid remnants were able to produce variable amounts of thy-

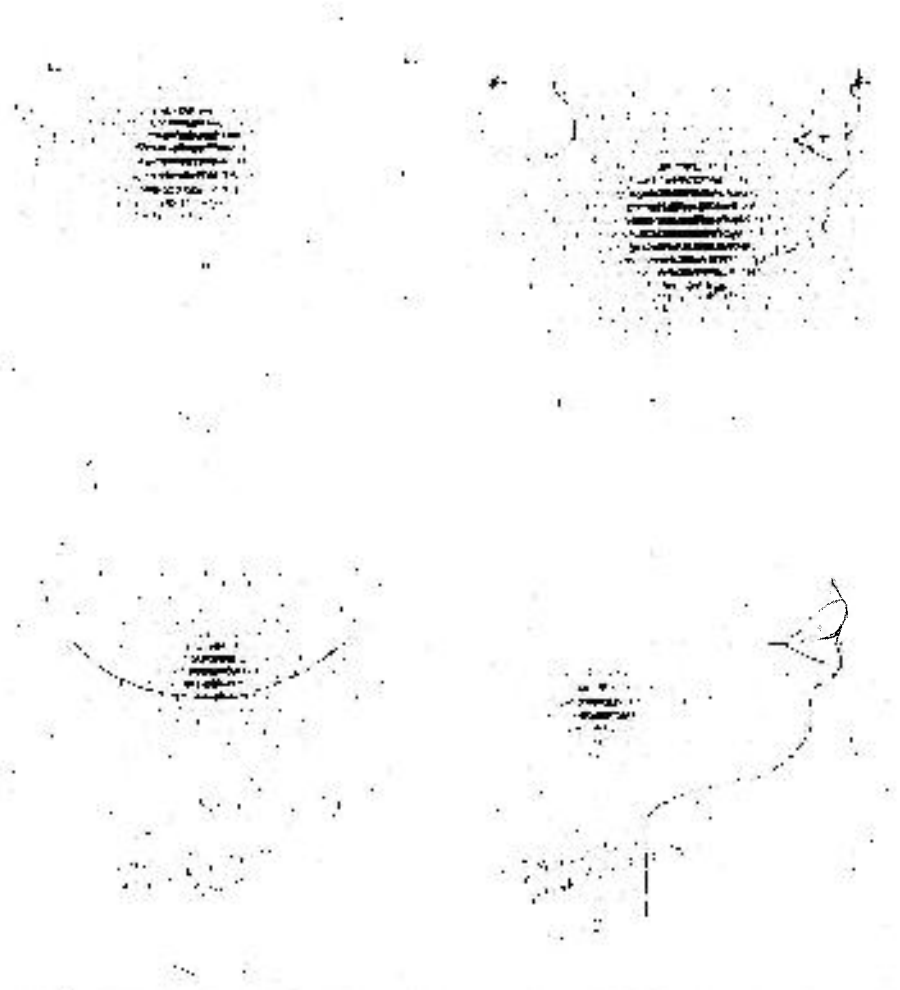


Fig. 6. Scans of the thyroid remnant (24 hours after radioiodine administration), from patients JNS (group 3 bottom) and from ENL (group 4 top).

roid hormone, accumulate radioiodine and respond to TSH stimulation. There was no detectable plasma antibodies against thyroglobulin. In groups one and two, an early and significant rise in the PBI was observed following TSH injection. Groups three and four were unable to respond to TSH. Thus, larger doses of TSH failed to affect the serum PBI in the latter groups. It was to similar types of patients that the designation of "low thyroid reserve" was most appropriately given (21).

No explanation could be given as to why patients with thyroid dysgenesis have such a discrepancy in the clinical picture and in response to TSH stimulation. It may be possible that in groups three and four persistently higher levels of endogenous TSH during postnatal life would be one of the factors involved in better thyroid function in these groups. Plasma TSH assay could possibly help clarify this point.

In conclusion, no definite cause for thyroid dysgenesis was found in these patients. Although response to the TSH test was not the same in two different groups, no definite conclusion was reached. It may be suggested that an unknown intra-uterine factor may act in the early stages of thyroid gland genesis, causing this anomaly. It is unlikely that this unknown factor is autoimmune, although it cannot be excluded as an acting recessive gene.

#### SUMMARY

Thirteen cases of ectopic thyroid tissue were followed for two years, divided into four groups:

*Group one:* (4 cases) presented a complete clinical picture of congenital hypothyroidism, with marked mental retardation.

*Group two:* (5 cases) developed hypothyroidism at different ages between 1-5 years; usually these patients exhibit a less severe clinical picture and variable mental retardation.

*Group three:* (2 cases) the hypothyroidism began at adolescence with normal sexual differentiation and intelligence, but a stunted growth.

*Group four:* (2 cases) euthyroid adults with a palpable mass at sublingual region and short stature.

No neurological signs of deaf-mutism were found among these patients. Familiar goiters or inbreeding were not found. Two cases, however, were found in the same family. Considerable delay in the bone age, and four cases of epiphyseal dysgenesis was observed in groups one and two. Radioactive scanning showed in all cases, a small, usually round mass of thyroid tissue in the upper middle cervical area. An attempt was made to correlate the size and weight of the mass with the clinical picture, giving negative results.

Two and six hours after a TSH stimulation test, a small increase in the PBI in groups one and two was noted. No response was observed in groups three and four. This may suggest a different level of endogenous TSH in those groups.

In eight patients and their respective mothers, agar diffusion and tanned red cell agglutinations tests were negative. These findings give little support for an autoimmune background for these patients. It is suggested that perhaps an intra-uterine factor may affect the normal glandular development. In nine cases



the thyroid remnant was able to provide sufficient hormone for normal intra-uterine and variable postnatal development.

## REFERENCES

1. VERNEUIL, DR.: *Arch. Gen. Med.* **1**:185, 1853.
2. HUNT, W.: *Am. J. Med. Sci.* **51**:163, 1866.
3. MONTGOMERY, M. L.: *West J. Surg.* **43**:661m, 1935.
4. SCHILLING, J. A., KARR, J. W. and HURSH, J. B.: *Surgery* **27**:130, 1950.
5. EINHORN, L. and LARSSON, L. J.: *Acta Radiol.* **45**:405, 1956.
6. MCCIRR, E. M. and HUTCHINSON, L. H.: *J. Clin. Endocr.* **15**:668, 1955.
7. KELLERSHOHN, C. and MARTIN, L.: *Acta Radiol.* **51**:137-156, 1959.
8. VAGUE, J., NICOLINO, J., FAVIER, G., MILLER, G., DROGUE, M. and CALOTHY, G.: *Ann. D'Endocrin. (Paris)* **24**:80, 1963.
9. ZELLIOTTO, O. and CARENZA, P.: *Acta Isotopica* **2**:51, 1962.
10. BARBERIO, J. C. *et al.* in Proc. Conf. Uses of Radiois. in Animal Biology and Med. Sci. Academic Press, London, 1963.
11. NAVAJAS, E.: *Rev. Paul. Med.* **50**:338, 1957.
12. BARKER, S. B.: *J. Biol. Chem.* **173**:715, 1948.
13. STRAUSS, A., MENDES, E., and ULHOA CINTRA, A. B.: *O Hospital (Rio de Janeiro)* **58** (4): 35, 1960.
14. LOBO, L. C. G. L.; POMPEU, F. and ROSENTHAL, D.: *Clin. Endocrin.* **23**:407, 1963.
15. BOTTURA, CÁSSIO: Thesis, Fac. Med. Univ. S. Paulo, 1953.
16. WERNER, S. (ed): *The Thyroid*, 2nd ed. Hoeber & Harper, New York, 1962.
17. CHANDLER, R. W., BLIZZARD, R. M., HUNG, W. and KYLE, M.: *N. Engl. J. Med.* **267**:376, 1962.
18. COSTA, A. MORTARA, M., COTTINO, F., PELLERITO, N., and DALL'AQUA, R.: *Ann. Endocrin.* **20**:17, 1959.
19. CLEMENTS, F. W.: *Bull WHO* **18**:175, 1958.
20. STANBURY, J. B., C. L. BROWNELL, D. S. RIGGS, M. PERINETTI, L. ITOIZ, and E. B. DEL CASTILLO: *Endocrine Control and the Adaptation of Man to Iodine Deficiency*, Harvard Univ. Press, Cambridge, 1954.
21. LEVY, R. P.: in Werner S. C. (ed.) *Thyrotropin*, Charles C Thomas, Springfield, 1963.