

LED Phototherapy to Prevent Mucositis: A Case Report

Leticia Lang-Bicudo, M.S.D.,¹ Fernanda De Paula Eduardo, Ph.D.,²
Carlos De Paula Eduardo, Ph.D.,³ and Denise Maria Zezell, Ph.D.⁴

Abstract

Objective: The purpose of this case report was to evaluate the efficacy of phototherapy using light-emitting diodes (LEDs) to prevent oral mucositis in a Hodgkin's disease patient treated with the ABVD (doxorubicin [Adriamycin], bleomycin, vinblastine, and dacarbazine) chemotherapy regimen. **Background Data:** Mucositis is a common dose-limiting complication of cancer treatment, and if severe it can lead to alterations in treatment planning or suspension of cancer therapy, with serious consequences for tumor response and survival. Therefore, low-power lasers and more recently LEDs, have been used for oral mucositis prevention and management, with good results. **Materials and Methods:** In this study, a 34-year-old man received intraoral irradiation with an infrared LED array (880 nm, 3.6 J/cm², 74 mW) for five consecutive days, starting on chemotherapy day 1. In each chemotherapy cycle, he received the ABVD protocol on days 1 and 15, and received LED treatment for 5 d during each cycle. To analyze the results, the World Health Organization (WHO) scale was used to grade his mucositis, and a visual analogue scale (VAS) was used for pain evaluation, on days 1, 3, 7, 10, and 13 post-chemotherapy. **Results:** The results showed that the patient did not develop oral mucositis during the five chemotherapy cycles, and he had no pain symptoms. **Conclusion:** LED therapy was a safe and effective method for preventing oral mucositis in this case report. However, further randomized studies with more patients are needed to prove the efficacy of this method.

Introduction

HODGKIN'S DISEASE IS A TYPE OF LYMPHOMA that occurs when specific lymph node cells start multiplying uncontrollably, causing a tumor. Among the chemotherapy protocols indicated for treatment, is ABVD (doxorubicin [Adriamycin], bleomycin, vinblastine, and dacarbazine), a drug combination that has been used effectively, even in advanced stages of the disease.¹ However, this type of treatment may bring toxicity, such as mucositis.

Chemotherapy or radiotherapy treatment frequently results in mucositis,^{2–4} which can lead to serious complications, such as fungal, viral, and bacterial infections,⁵ capable of causing systemic infection.^{2,6,7} As it is a severe and limiting complication of cancer treatment, several alternatives have been used in an effort to prevent and treat oral mucositis.⁷ So far, however, mucositis treatment is palliative, consisting of diminishing the symptoms and preventing infection.^{6,9} In recent decades, low-level laser irradiation has appeared as a

new treatment option to reduce tissue inflammation,⁸ and has led to good results in mucositis treatment.^{5,7,10,11}

Some recent researchers have suggested that another alternative to control mucositis is to use light-emitting diodes (LEDs), devices emitting monochromatic diffuse light of a wavelength effective for tissue healing.^{2,12–14} These studies suggested that lasers,^{10,15–18} as well as LEDs,^{2,19,20} can be effective for biostimulation, pain relief, and healing.

The main advantage of LEDs over lasers, besides their lower cost, is that LED systems allow a larger area to be treated in a short time, with a large bandwidth (at several wavelengths),¹² whereas typical laser systems irradiate only small spots (a few millimeters). Recent studies have shown the efficacy of using LEDs to diminish the pain and intensity of oral mucositis in patients having bone marrow transplantation (BMT)^{12,19,20} and chemotherapy-induced mucositis.² Treatment with LEDs accelerates normal healing and tissue regeneration without producing overgrowth or neoplastic transformation.²⁰

¹Mestre Profissional em Lasers em Odontologia IPEN/USP, ²Hospital Israelita Albert Einstein, ³Laboratório Especial de Laser na Odontologia (LELO), Departamento de Dentística, Faculdade de Odontologia, Universidade de São Paulo, and ⁴Centro de Lasers e Aplicações IPEN-CNEN, São Paulo, Brazil.

Materials and Methods

The patient selected for this study, a 34-year-old man undergoing chemotherapy treatment with the ABVD protocol for Hodgkin's lymphoma, was admitted to Amavita Cancer Clinic in Bauru, São Paulo, Brazil. He gave signed consent and was instructed about mouth hygiene and oral care, and to use a mouthwash and a long-term saliva substitute, both from Biotène® (Laclede, Inc., Rancho Dominguez, CA), throughout the entire study period. The ethics board of Instituto de Pesquisas Energéticas e Nucleares (IPEN) accepted and approved the study design (number 103/CEP-IPEN/SP).

The LED system (MMOptics Ltd., São Carlos, SP, Brazil) consists of a handpiece with seven individual LEDs in a circular arrangement (Fig. 1) with an output diameter of 12.5 mm, and having an acrylic pointer at the end. The LEDs emit at 880-nm wavelength, with power of 74 mW at the acrylic tip.

At each session, five anatomic areas of the mouth were irradiated as shown in Fig. 2: the buccal mucosa, the lower labial mucosa, the lateral tongue, the upper tongue portions, and the floor of the mouth.

The dose used was approximately 3.6 J/cm² per point. To cover all the areas described, 27 points were necessary, with each point received 60 sec of irradiation, totaling 27 min per session. Irradiation began on chemotherapy day 1 (D1) and continued daily until the fifth day (D5). For each chemotherapy cycle, the patient received two rounds of chemotherapeutic drugs, according to the ABVD protocol, the second occurring 15 d after the first. With each drug administration, another LED irradiation session was given, starting the count again as day 1 (D1). Therefore, in each chemotherapy cycle he received LED irradiation on 10 d, five after each round of drug administration. All infection control procedures were followed, and both the patient and the professional wore protective glasses to ensure their safety.

To check the results, the irradiated areas were photographed. A trained examiner evaluated the photos to establish the degree of severity of the mucositis in accordance with the World Health Organization (WHO)²¹ scale. Pictures were taken after each chemotherapy cycle, for both 5-day phases, on days 1, 3, 7, 10, and 13. With regard to pain as-



FIG. 1. Handpiece with seven LEDs.

assessment, the patient himself noted the pain intensity on each clinical evaluation day (coinciding with the photographic evaluation), by filling out a visual analogue scale (VAS)²².

Results

The patient received LED irradiation according to the methodology described above, for five chemotherapy cycles, and had no oral mucositis of any degree throughout treatment. Consequently, the patient also had no pain during the entire process.

The patient tolerated the LED irradiation well during the five chemotherapy cycles, which totaled 50 irradiation sessions, since there were 10 sessions per cycle.

Due to these excellent results, the patient could continue his normal activities of daily living during all five chemotherapy cycles, with no interruption in his work activities. There was no need for hospitalization, or parenteral or enteral nutritional supplementation. There also was no need for any analgesia during chemotherapy. The patient could eat normally and did not show any signs of dehydration.

There was no need for fungal medications or other infection control measures, as there were no oral lesions, meaning that there was no significant risk of systemic infections due to oral mucositis.

These good oral results seen during chemotherapy made it possible for the patient to tolerate the therapy well, and no interruptions of chemotherapy were necessary. The patient was also had no depressive symptoms during treatment, and the patient maintained a good emotional state.

Discussion

The results of this study show that LEDs are quite safe, and they did not cause the patient any side effects or discomfort. These same results were also found in other studies of the use of low-level lasers^{6,9,18,21,23-26} and LEDs^{2,12} used to prevent and treat oral mucositis.

It is important to mention that all other patients treated at our clinic with this chemotherapy regimen developed oral mucositis to different degrees, and this was the first case that did not present this complication.

Our results agree with those of other previously published studies. However, there are no similar studies in the literature that specifically evaluated this chemotherapy protocol. Usually, oral mucositis prevention studies are conducted in BMT patients, because BMT involves not only aggressive conditioning drug regimens with several and drugs being given at once, but the patients are under inpatient hospital care, which makes laser or LED studies easier to perform since they require daily irradiation sessions.

In this case study, the patient had no oral mucositis, suggesting that the LED treatment was efficient for preventing ulcers, and consequently pain, as was also shown in the study by Whelan et al.,¹² which studied the use of LEDs (Quantum Devices, Barneveld, WI, USA) for oral mucositis prevention in pediatric patients undergoing BMT. The results showed that of the 32 participating patients, 3 had no oral mucositis, thus 10% of their patients had results identical to those of our study.

The study by Migliorati et al.²³ also had similar results; however, they used low-level laser (infrared AsGaAl) therapy. Of the 11 irradiated patients, two received high doses

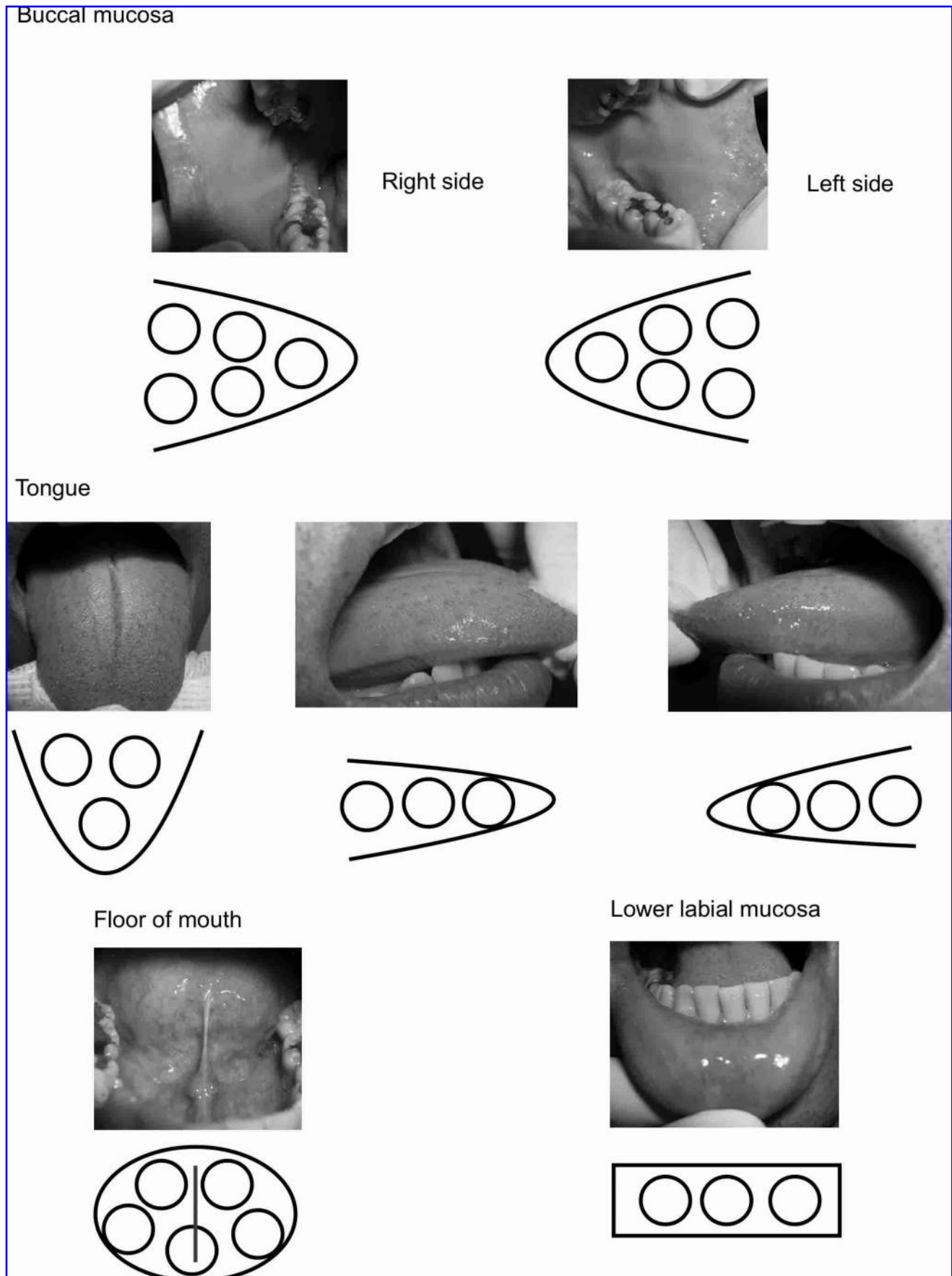


FIG. 2. The irradiated areas and the 27 irradiation points.

of chemotherapy (and one received doxorubicin, a drug also used by our patient), and one also had no oral mucositis, and thus did not have any painful symptoms. The remaining patients developed mucositis of varying degrees, but none experienced maximal levels of pain.

The study by Bensadoun et al.²¹ showed that He-Ne laser treatment substantially diminished the degree of oral mucositis seen, although it did not prevent the appearance of lesions. As a result, the control group patients had 3rd-degree mucositis for 37 wk (35%), compared with 8 wk (7%) for the laser group.

With regards to the methodology, we opted for daily irradiations on five consecutive days, always starting on chemotherapy day 1. This methodology coincides with that used in previous studies.^{6,25} Irradiations were started on the same day as chemotherapy to prevent mucositis lesions from appearing, because we believed the preventive action of the LEDs resulted from biomodulating the inflammatory process that occurs in the first days,²⁷ soon after drug administration. However, in other studies, laser or LED irradiation did not begin at the same time as cancer therapy, for example, the study by Whelan et al.,¹² in which LED irradiation began on the first day after BMT, and not on the first day of BMT conditioning. This difference was also seen in the study by Barasch et al.,²⁴ in which patients started He-Ne laser therapy the day after the patients ended their conditioning regimen, one or two days before BMT.

In this study, irradiation began on chemotherapy day 1, whereas in some other published studies the authors began laser therapy at other time points before or after BMT,^{12,24} meaning that they may have affected other phases of the progression of oral mucositis, and thus got different results. So these other authors, that began irradiation after drug administration, may have affected more advanced phases of mucositis, when it is past the inflammatory stage, unlike the methodology we adopted.

A 5-day irradiation period was adopted in the present study. This differed from other studies, some of which chose to irradiate patients for a longer period, as observed in the study by Migliorati et al.,²³ who irradiated patients for 10 d.

Our methodology takes into consideration the phases of oral mucositis, and we endeavored to act before the ulcerative phase began. As the ulcerative phase occurs approximately 7 d after drug administration,²⁸ it seemed reasonable for irradiation to last no more than 7 d, and thus the LED therapy was meant to be prophylactic. We believe treatment beyond this period would only affect healing, and is thus no longer preventive.

Sandoval et al.²⁶ reported an example of this healing action, in which lesions were irradiated only when mucositis symptoms first appeared. Based on a functional scale, the results showed that grade 3 mucositis was reduced in 42% of cases. Based on clinical aspects, grade 4 mucositis was reduced in 75% of patients.

The patient in our case report had no painful symptoms, since there was no oral mucositis. Thus pain could not be evaluated, since the efficacy of LEDs in reducing pain could only be assessed if there were lesions, and some studies have shown that pain intensity is directly related to the degree of oral mucositis present.

With regard to the anatomic areas we chose for LED irradiation in this study, sites mainly in nonkeratinized mucosa

were targeted, areas where the incidence of oral mucositis is higher according to the results of previous studies.^{4,29}

With regard to comfort, the lasers or LEDs used must be adjusted to minimize irradiation time, in order to shorten treatment sessions. Equipment is now being designed for this purpose, devices that use clusters of emitters that allow extra-oral irradiation, such as the device shown in the study by Whelan et al.¹² This is also advantageous, because if irradiation can be performed extra-orally, this allows one to avoid working inside the patient's mouth, and thus avoid any problems if nausea or vomiting occurs. In that study the irradiation time for a 4-J/cm² dose was approximately 71 sec for each side, whereas in our study it was 27 min total.

The LED intra-oral irradiation equipment used in our study proved to be very effective in preventing oral mucositis, which was the goal of the study. We emphasize, however, that mucositis has complex pathology, and it is difficult to accurately determine which patients may develop lesions.³⁰ Although many factors in this case could have led to mucositis (the patient was young, he was undergoing an aggressive chemotherapy protocol with a high frequency of drug administration), this patient may not have had any lesions regardless of any preventive treatment given.

Since this case report is about only a single patient, it is impossible to verify the efficacy of the therapy; however, the results are nonetheless heartening. We believe this case report may be helpful, mainly in indicating the proper therapeutic regimen to pursue, and will serve as a basis for further randomized studies to assess whether the therapy is indeed effective in a variety of patients, and it has the potential to provide them with a much improved quality of life during cancer treatment.

Conclusion

In this study, LED therapy was shown to be a safe and effective method of preventing oral mucositis in a patient undergoing ABVD chemotherapy for Hodgkin's disease, using the protocol described in this case report.

Disclosure Statement

No conflicting financial interests exist.

References

1. Kaufman, D., and Longo, D.L. (2000). Hodgkin's disease, in: *Clinical Oncology*. M.D. Abeloff, J.O. Armitage, A.S. Lichter, and J.E. Niederhuber, (eds.). Philadelphia: Churchill Livingstone, pp. 2620–2657.
2. Corti, L., Chiarion-Sileni, V., Aversa, S., et al. (2006). Treatment of chemotherapy-induced oral mucositis with light-emitting diode. *Photomed. Laser Surg.* 24, 207–213.
3. Sonis, S.T., Sonis, A.L., and Lieberman, A. (1978). Oral complications in patients receiving treatment for malignancies other than of the head and neck. *J. Am. Dent. Assoc.* 97, 468–472.
4. McGuire, D.B., Altomonte, V., Peterson, D.E., Wingard, J.R., Jones, R.J., and Grochow, L.B. (1993). Patterns of mucositis and pain in patients receiving preparative chemotherapy and bone marrow transplantation. *Oncol. Nurs. Forum* 20, 1493–1502.

5. Nes, A.G., and Posso, M.B.S. (2005). Patients with moderate chemotherapy-induced mucositis: pain therapy using low intensity lasers. *Int. Nurs. Rev.* 52, 68–72.
6. Cowen, D., Tardieu, C., Schubert, M., et al. (1997). Low energy helium-neon laser in the prevention of oral mucositis in patients undergoing bone marrow transplant: results of a double blind randomized trial. *Int. J. Radiat. Oncol. Biol. Phys.* 38, 697–703.
7. Genot, M.T., and Klastersky, J. (2005). Low-level laser for prevention and therapy of oral mucositis induced by chemotherapy or radiotherapy. *Curr. Opin. Oncol.* 17, 236–240.
8. Quadri, T., Bohdanecka, P., Tunér, J., Miranda, L., Altamash, M., and Gustafsson, A. (2007). The importance of coherence length in laser phototherapy of gingival inflammation—a pilot study. *Lasers Med. Sci.* 22, 245–251.
9. Bensadoun, R.J., and Ciais, G. (2002). Radiation- and chemotherapy-induced mucositis in oncology: results of multicenter phase III studies. *J. Oral Laser Applic.* 2, 115–120.
10. Ribeiro, M.S., and Zezell, D.M. (2004). Laser de baixa intensidade, in: *A Odontologia e o Laser—Atuação do Laser na Especialidade Odontológica*. N. Gutknecht, and C.P. Eduardo, (eds.). São Paulo: Quintessence Editora, pp. 217–240.
11. Saadeh, C.E. (2005). Chemotherapy- and radiotherapy-induced oral mucositis: review of preventive strategies and treatment. *Pharmacotherapy.* 25, 540–554.
12. Whelan, H.T., Connelly, J.F., Hodgson, B.D., et al. (2002). NASA light-emitting diodes for the prevention of oral mucositis in pediatric bone marrow transplant patients. *J. Clin. Laser Med. Surg.* 20, 319–324.
13. Whelan, H.T., Buchmann, E.V., Dhokalia, A., et al. (2003). Effect of NASA light-emitting diode irradiation on molecular changes for wound healing in diabetic mice. *J. Clin. Laser Med. Surg.* 21, 67–74.
14. Whelan, H.T., Houle, J.M., Donohoe, D.L., et al. (1999). Medical applications of space light-emitting diode technology—space station and beyond. *Space Technol. Appl. Int. Forum* 458, 3–15.
15. Karu, T. (1988). Molecular mechanism of the therapeutic effect of low-intensity laser radiation. *Laser Life Sci.* 2, 53–74.
16. Ribeiro, M.S., and Zezell, D.M. (2004). Laser em baixa intensidade, in: *Tratado de Medicina Estética*. M. Maio, (ed.). São Paulo: Roca, pp. 1149–1166.
17. Enwemeka, C., Parker, J.C., Dowdy, D.S., Harkness, E.E., Sanford, L.E., and Woodruff, L.D. (2004). The efficacy of low-power lasers in tissue repair and pain control: a meta-analysis study. *Photomed. Laser Surg.* 22, 323–329.
18. Schubert, M.M., Eduardo, F.P., Guthrie, K.A., et al. (2007). A phase III randomized double-blind placebo-controlled clinical trial to determine the efficacy of low level laser therapy for the prevention of oral mucositis in patients undergoing hematopoietic cell transplantation. *Support. Care Cancer* 15, 1145–1154.
19. Whelan, H.T., Smits, R.L. Jr., Buchmann, E.V., et al. (2001). Effect of NASA light-emitting diode irradiation on wound healing. *J. Clin. Laser Med. Surg.* 19, 305–314.
20. Whelan, H.T., Buchmann, E.V., Whelan, N.T., et al. (2001). NASA light emitting diode medical applications from deep space to deep sea. *Space Technol. Appl. Int. Forum* 552, 35–45.
21. Bensadoun, R.J., Franquin, J.C., Ciais, G., et al. (1999). Low-energy He/Ne laser in the prevention of radiation-induced mucositis. A multicenter phase III randomized study in patients with head and neck cancer. *Support. Care Cancer* 7, 244–252.
22. Schubert, M.M., Williams, B.E., Lloid, M.E., Donalson, G., and Chapko, M.K. (1992). Clinical assessment scale for the rating of oral mucosal changes associated with bone marrow transplantation: development of an oral mucositis index. *Cancer.* 69, 2469–2477.
23. Migliorati, C., Massumoto, C., Eduardo, F.P., et al. (2001). Low-energy laser therapy in oral mucositis. *J. Oral Laser Applic.* 1, 97–101.
24. Barasch, A., Peterson, D.E., Tanzer, J.M., et al. (1995). Helium-neon laser effects on conditioning-induced oral mucositis in bone marrow transplantation patients. *Cancer.* 76, 2550–2556.
25. Tardieu, C., Cowen, D., Charpin, C., and Franquin, J.C. (1998). Effects of 60 Mw HeNe laser on oral mucosa, in: *Proceedings of the 6th International Congress on Lasers in Dentistry*. G.L. Powell, and J. Frame, (eds.). Salt Lake City: University of Utah, pp. 24–27.
26. Sandoval, R.L., Koga, D.H., Buloto, L.S., Suzuki, R., and Dib, L.L. (2003). Management of chemo- and radiotherapy induced oral mucositis with low-energy laser: initial results of A.C. Camargo Hospital. *J. Appl. Oral Sci.* 11, 337–341.
27. Sonis, S.T., Elting, L.S., Keefe, D., et al. (2004). Perspectives on cancer therapy-induced mucosal injury: pathogenesis, measurement, epidemiology, and consequences for patients. *Cancer Suppl.* 100, 1995–2025.
28. Kolbinson, D.A., Schubert, M.M., Flournoy, N., and Truelove, E.L. (1988). Early oral changes following bone marrow transplantation. *Oral Surg. Oral Med. Oral Pathol.* 66, 130–138.
29. Woo, S.B., Sonis, S.T., Monopoli, M.M., and Sonis, A.L. (1993). A longitudinal study of oral ulcerative mucositis in bone marrow transplant recipients. *Cancer.* 72, 1612–1617.
30. Barasch, A., and Peterson, D.E. (2003). Risk factors for ulcerative oral mucositis in cancer patients: unanswered questions. *Oral Oncol.* 39, 91–100.

Address reprint requests to:
 Leticia Lang Bicudo, M.S.D.
 Rua Ernani Lacerda de Athayde, 210, ap. 1201
 Londrina, Parana, Brasil

E-mail: leticialang@hotmail.com