



This article was published in an Elsevier journal. The attached copy is furnished to the author for non-commercial research and education use, including for instruction at the author's institution, sharing with colleagues and providing to institution administration.

Other uses, including reproduction and distribution, or selling or licensing copies, or posting to personal, institutional or third party websites are prohibited.

In most cases authors are permitted to post their version of the article (e.g. in Word or Tex form) to their personal website or institutional repository. Authors requiring further information regarding Elsevier's archiving and manuscript policies are encouraged to visit:

<http://www.elsevier.com/copyright>

available at www.sciencedirect.comjournal homepage: www.intl.elsevierhealth.com/journals/arob

Short communication

Effects of low-power red laser on dentine–pulp interface after cavity preparation. An ultrastructural study

Bruno Miranda Godoy^a, Victor Elias Arana-Chavez^c, Silvia Cristina Núñez^b,
Martha Simões Ribeiro^{b,*}

^a Professional Master Lasers in Dentistry, IPEN-CNEN/SP, São Paulo, Brazil

^b Center for Lasers and Applications, IPEN-CNEN/SP, São Paulo, Brazil

^c Department of Cell and Developmental Biology, ICB-USP, São Paulo, Brazil

ARTICLE INFO

Article history:

Accepted 5 February 2007

Keywords:

Dental cavity preparation

Dental pulp

Laser therapy

Odontoblasts

Transmission electron microscopy

ABSTRACT

Objective: Studies on the influence of low-power red laser on the repair of dental structures are very scarce. This study investigated the effects of the laser therapy on the ultrastructure of the dentine–pulp interface after conservative class I cavity preparation.

Design: Two female volunteers with 8 premolars indicated for extraction for orthodontic reasons were recruited. Class I cavities were prepared and the teeth were randomly divided into two groups. The first group received treatment with a GaAlAs laser, $\lambda = 660$ nm, power of 30 mW and energy dose of 2 J/cm², directly and perpendicularly into the cavity in a single visit. After the irradiation, the cavities were filled with composite resin. The second group received the same treatment, except by the laser therapy.

Results: Twenty-eight days post-preparation, the teeth were extracted and processed for transmission electron microscopy analysis. Two sound teeth, without cavity preparation, were also studied. The irradiated group presented odontoblast process in higher contact with the extracellular matrix and the collagen fibrils appeared more aggregated and organised than those of control group. These results were also observed in the healthy teeth.

Conclusion: These findings suggest that laser irradiation accelerates the recovery of the dental structures involved in the cavity preparation at the predentine region.

© 2007 Elsevier Ltd. All rights reserved.

1. Introduction

Dental restorative procedures are a source of injury to the pulp tissue. In many circumstances, a caries lesion does not represent the biggest threat to the pulp tissue; but instead, the surgical techniques and materials employed to restore the tooth configuration may represent the source of aggression. The aggression to the pulp tissue may occur due to several

factors including heat provoked during cavity preparation, method of placement of the restorative material, chemical irritants, among others.¹

Dentinogenesis is a continuous and dynamic process regulated by a single layer of highly differentiated post-mitotic odontoblast cells.¹ Dentine matrix secreted by odontoblasts is the major constituent of the dental mineralized tissue being composed of inorganic and organic components. The

* Corresponding author. Tel.: +55 11 3816 9313; fax: +55 11 3816 9315.

E-mail address: marthasr@usp.br (M.S. Ribeiro).

0003-9969/\$ – see front matter © 2007 Elsevier Ltd. All rights reserved.

doi:10.1016/j.archoralbio.2007.02.003

inorganic components are mostly hydroxyapatite and water. Collagen fibrils and non-collagenous proteins are the organic segment secreted by odontoblasts.^{2,3}

The objective of a regenerative pulp treatment is to reconstitute normal tissue continuum at the pulp-dentine border, regulating tissue-specific processes of tertiary dentinogenesis. Tertiary dentine is synthesized as a response to various external stimuli, such as dental caries, attrition and trauma and may be divided into two sub-categories, the reactionary dentine and the reparative dentine.² The reactionary dentine as well as the reparative dentine is the best protection material to dental pulp since the tubular pattern of the reparative dentine varies from a discontinuous to an atubular nature, and thus, the reparative dentin matrix permeability is reduced and diffusion of noxious agents from the tubules is prevented.⁴

Therapeutic effects obtained with low-power laser are used for several endings in dentistry, such as acceleration of the healing process, bone regeneration, attenuation of aching processes, tooth decay prevention, etc.^{5–10} Some works suggest the biomodulation influence of laser radiation on the inflammatory and reparative process in pulp tissue, showing that low-intensity laser therapy (LILT) can be used as a helper on tertiary dentine formation.¹¹ In the aforementioned works, the low-intensity laser radiation was used after cavity preparations with pulp exposition. Such preparation is aggressive and it is not the major cavity preparation performed in dental offices on a daily basis.

It is unclear which cavity preparation depth would promote little or no pulp injury. Moreover, it is also unclear the pulp response to different cavities preparation depth and to different restorative materials.¹² Besides the depth of the cavity preparation, the dentinal tubule permeability, as aforementioned, is also an important factor, since tubule permeability allows the progression of caries, bacterial leakage and chemical irritants towards pulp tissue.¹³ The best protection of the pulp tissue is offered by the dentine secreted by the odontoblasts. So far, there is not an artificial material that can be placed into a tooth that would provide better protection to the pulp. Therefore, the preservation of the odontoblast cells must be a goal of the restorative dental treatment.

Thus, the proposal of this paper is to evaluate ultrastructurally, by transmission electron microscopy, the effects of red emission laser on the pulp–dentine interface after conservative cavity preparation and restoration with composite resin without pulp exposition, looking for any beneficial effects of this therapy on the dentin repair process.

2. Material and methods

Ethical approval was obtained from the School of Dentistry–University of São Paulo's Research Ethical Committee. After written consent was given, two female patients, aged 24 and 27 years, had six class I cavities prepared in non-carious intact premolars teeth, which were scheduled for extraction for orthodontic reasons. The patients were anaesthetized, and pre-operative radiographs were taken. The cavities were prepared under absolute isolation to avoid contamination of

the teeth. Standard cavity preparations were cut into occlusal dentine with a diamond bur using the least pressure at a drill speed of 4000 rpm with water spray coolant. Regular 2 mm width × 5 mm depth cavities were performed, finishing at dentine level, without pulp exposure. Since all elements were free of dental caries prior to preparation, the depth of the cavities could be standardised.

The teeth were washed and cleaned with pumice and water. The samples were, then, divided into two groups. The laser group (LG) had the cavity irradiated with the continuous emission GaAlAs ($\lambda = 660$ nm) diode laser (LLLT-Biowave-Kondortech, S. Carlos, Brazil), 2 mm beam diameter with a 20° of beam divergence, maximum output power of 30 mW. A radiant exposure of 2 J/cm² was applied.^{5,11} The beam was applied directly into the pulpal wall of the cavity for 2 min and 15 s. The teeth were restored with composite resin (Z250, 3 M, St. Paul, MN, USA) according to manufacturer's instructions. The control group (CG) had cavities prepared and restored as previously described. The teeth in this group did not receive laser irradiation.

Two healthy teeth remained without cavity preparation and were also analysed.

Teeth of each group were extracted under local anaesthesia 28 days after the procedure. The teeth were cleaned and all soft tissues covering the root surface were carefully removed. The samples were immediately immersed in 2% glutaraldehyde plus 2.5% formaldehyde buffered with 0.1 M sodium cacodylate, pH 7.4. Specimens were immersed in a beaker containing 40 mL of fixative at room temperature, which was placed in a 20 cm × 20 cm glass recipient filled with ice and placed in a Pelco 3440 laboratory microwaves (MW) oven (Ted Pella; Redding, CA). The temperature probe of the oven was submerged in the fixative and the specimens were exposed to MW irradiation at a 100% setting for three periods of 5 min with the temperature programmed to a maximum of 37 °C.¹⁴ After MW irradiation, the samples were transferred to fresh fixative and remained in it overnight at 4 °C. The specimens were washed in 0.1 M sodium cacodylate buffer, pH 7.2 for 1 h. Decalcification was made in an aqueous solution of 4.13% EDTA, replaced every 48 h, during approximately 6 months.

The samples were dehydrated in graded concentrations of ethanol and embedded in Spurr resin. Toluidine blue-stained 1- μ m-thick sections were analysed in a light microscope and regions of the interface pulp–dentine were selected for ultrathin sections. Ultrathin cuts (80 nm) were made from the chosen region by using a diamond ultramicrotome (Leica Ultra cut E). The specimens were analysed in a transmission electron microscope (JEOL 1010, JEOL Inc., Japan), operating at 80 kV.

3. Results

The ultrastructural analysis of the interface dentine–pulp, 28 days post-cavity preparation, showed that the teeth irradiated with red laser presented more organised collagen fibrils and less retraction in the odontoblast process compared to prepared non-irradiated premolars. The junctional complexes among odontoblasts were not altered.

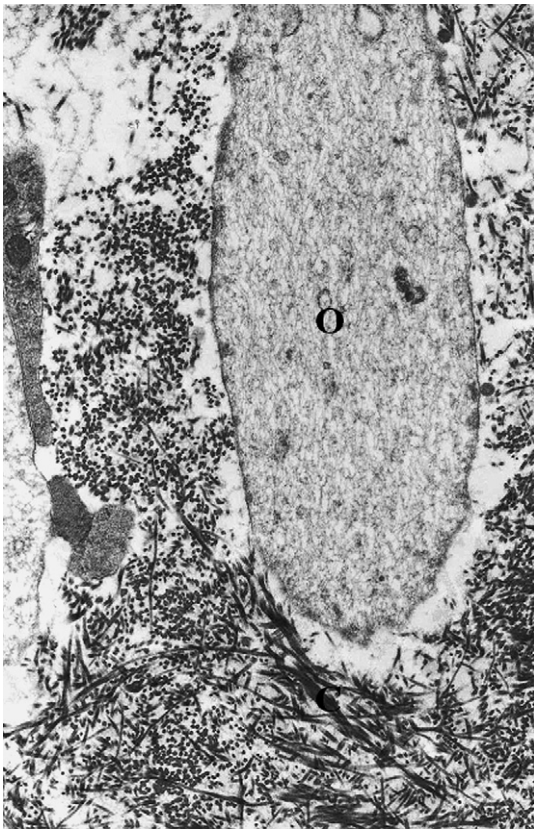


Fig. 1 – Electron micrograph of predentine region in the pulp–dentine interface of a premolar without cavity preparation. It can be noticed the odontoblast process (O) totally in contact with the collagen fibrils (C) of the extracellular matrix. $\times 12,000$.

The healthy teeth samples without cavity preparation showed an odontoblast process totally in contact with the collagen fibrils of the extracellular matrix (Fig. 1). It was also observed the junction area of two odontoblasts bodies (Fig. 2).

The teeth in LG that had their class I cavities irradiated with laser exhibited the odontoblast process in a bigger outline contact with extracellular matrix than CG samples (Fig. 3). The odontoblast body did not show significant morphological changes compared with healthy samples.

The samples in CG, which did not receive laser irradiation, showed spaced collagen fibrils in the extracellular matrix and a retracted odontoblast process (Fig. 4). It could also be observed in the predentine, some collagen fibrils forming scattered collagen fibrils. No significant morphological differences were observed in the junctional area between the odontoblasts comparing to healthy samples.

4. Discussion

The ultrastructural analysis at the pulp–dentine interface 28 days post-cavity preparation in teeth irradiated with low-intensity red laser, fluence of 2 J/cm^2 , showed more organised collagen fibrils on predentine and less retraction of the odontoblast process, compared to premolars that were

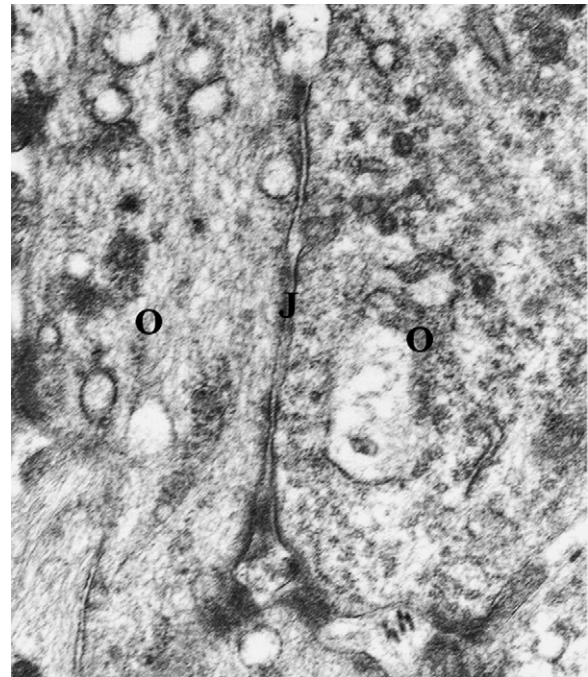


Fig. 2 – Electron micrograph of predentine region in the pulp–dentine interface of a premolar without cavity preparation. It can be observed two odontoblasts (O) and the junctional region (J) between them. $\times 40,000$.

restored without irradiation. Morphologically, the lased samples are similar to the healthy specimens without cavity preparation. Regarding to junction area, no significant differences were observed among the groups.

LILT is being recommended for some authors due to its analgesic and anti-inflammatory effects over the pulp tissue, promoting the patient comfort and the healing after an aggression.^{5,11,15} In this study, a conservative cavity preparation was chosen, and as the samples were free of cavities the injury caused to the pulp tissue was due to the cavity prepare and to the restorative process. Under such conditions, a dental structure recovery is expected. According to Murray et al., a remaining dentine thickness of 0.5 mm or greater is necessary to avoid evidence of pulp injury.¹² Constantly improved dental materials are being developed with increased mechanical and aesthetic properties, although these materials are not completely innocuous to dental pulp. Accorinte et al. demonstrated that dental pulps covered with adhesive system were inflamed or necrotic.¹⁶ Thus, the restorative process can represent by itself an aggression to the pulp tissue.

The sample characteristics are of great importance for this type of study, since dentine deposition occurs during the whole life.² Thus, the donor's characteristics as age, occlusal status and historic of dental trauma can promote alterations in the dentin deposition and in the pulp response. The donors in this study presented similar ages (24 and 27 years old) and hence the pulp tissue presents similar conditions relating to pulp size and quantity of deposited dentin.

The schedule of dental extraction was based on past work that showed an increased dentine production in rats' irradiated-molars 28 days after cavity preparation compared to

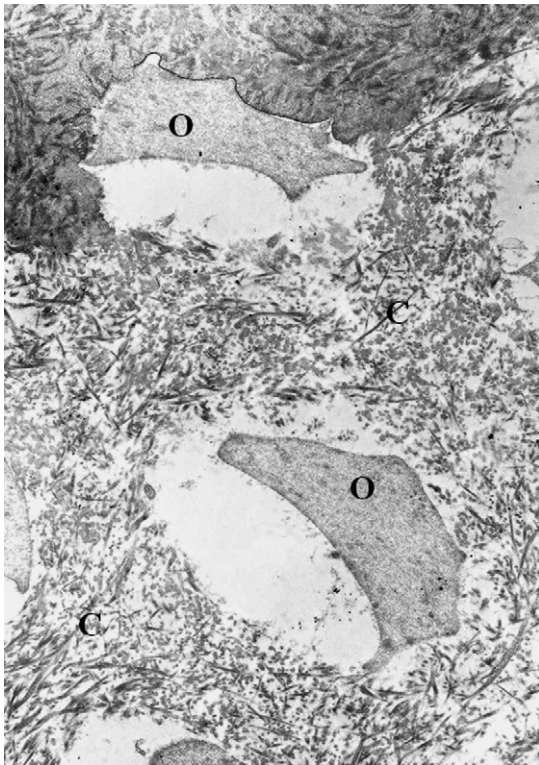


Fig. 3 – Electron micrograph of predentine region in the pulp–dentine interface of a premolar that had cavity prepared and did not receive laser treatment 28 days post-preparation. Note the odontoblast process (O) restrained without filling completely the space in contact with the collagen fibrils (C) of the extracellular matrix. $\times 15,000$.

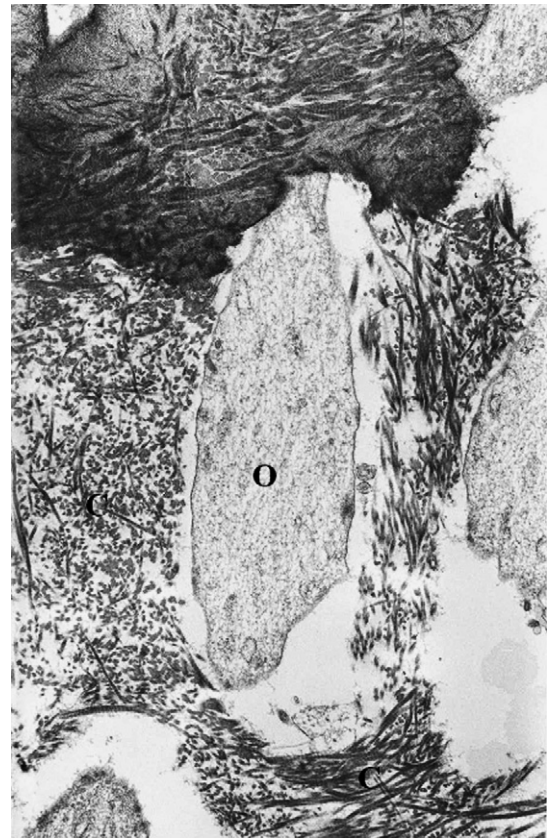


Fig. 4 – Electron micrograph of predentine region in the pulp–dentine interface of a premolar that had cavity prepared and received laser treatment, 28 days post-preparation. Observe the odontoblast process (O) in contact with the collagen fibrils (C) of extracellular matrix, which are more aggregated. $\times 22,500$.

non-irradiated samples.⁵ Studies in literature indicate that LILT may be used as an aide on dentine formation.^{5,11} In this study, on the CG specimens, a restrained odontoblast process was observed (see Fig. 3). Although the retraction may be artifactual, all the samples, including LG specimens, received the same processing and preparation, and they were all processed at the same time. Moreover, control group also showed collagen fibrils more randomly disperse in the extracellular matrix when compared to laser group (compare Figs. 3 and 4).

It is well-known that during the healing process, the collagen fibrils initially present a random distribution. As the healing process continues the collagen fibrils become more organised, thus, the organization of the collagen fibrils can be used as an indicative of the healing stage. The findings of this work suggest that laser radiation may accelerate the recovery of dental tissues, since the irradiated samples presented higher organization of the collagen fibrils in the extracellular matrix than the non-irradiated samples.

The wavelength of 660 nm used in this study was based on previous works.^{5,11} According to Kimura et al., this wavelength does not affect the dentin morphologically and a fraction of the incident radiation is transmitted through dentine and reaches the pulp tissue. In addition, red lasers at several wavelengths with output power range from 30 to 60 mW do not cause significant intrapulpal temperature rise, therefore, these laser devices used at correct parameters do not damage

the pulpal tissue.¹⁷ The results obtained in this study, confirm these data since odontoblast damage was not observed after laser irradiation. Junctions between the odontoblast cell bodies did not present significant changes among the specimens. In fact, the red laser physical properties permit a high penetration in hard tissue since its absorption by water and dental mineral content is low. Beside the wavelength, it is also important to state the relevance of other laser parameters as fluence, irradiance, frequency, etc., that can affect the outcome. In this work, the fluence used was $2\text{J}/\text{cm}^2$ in a single application, based on previous works,^{5,11} and also it was chosen to provide a feasible application, since the process involved in dental cavity prepare and restoration is made on a single day procedure. According to the results, the applied parameters are appropriated to accelerate the dental structure recovery. Meanwhile, the mechanisms involved remain multiple and unclear leading to questions regarding reproducibility and effectiveness. Thus, further works are necessary to clarify the exact method of action of the low-intensity laser radiation over dental tissues. Although the mechanisms involved remain indistinct, this study demonstrated the security of this therapy under the aforementioned parameters and the results indicated acceleration into the recovery of dental structures after cavity preparation with a single

application, and due to its practicality further efforts must be made in order to introduce this therapy on routine clinical practice.

Acknowledgements

The authors would like to thank Dr. Rosely Cordon, for her collaboration on this research, and would like to express their deep gratitude to Dr. Eduardo de Bortolli Groth (*in memoriam*).

REFERENCES

- [1] Murray PE, About I, Lumley PJ, Franquin J-C, Remusat M, Smith AJ. Human odontoblast cell number after dental injury. *J Dent* 2000;**28**:277–85.
- [2] Arana-Chavez VE, Massa LF. Odontoblasts: the cells forming and maintaining dentine. *Int J Biochem Cell Biol* 2004;**36**:1367–73.
- [3] Braut A, Kollar EJ, Mina M. Analysis of the odontogenic and osteogenic potentials of dental pulp in vivo using a Col1a1-2.3-GFP transgene. *Int J Dev Biol* 2003;**47**:281–92.
- [4] Tziafas D, Smith AJ, Lesot H. Designing new treatment strategies in vital pulp therapy. *J Dent* 2000;**28**:77–92.
- [5] Brugnera Jr A, Garrini AEC, Pinheiro ALB, Campos DHS, Donamaria E, Magalhães F, et al. LLLT in treating dentinary hypersensitivity: a histologic study and clinical application. Rechmann P, Fried D, Hennig T, editors. *Lasers in dentistry IX Proc SPIE*, vol. 4950. 2003:p. 46–53.
- [6] Myers TD. Laser in dentistry. *J Am Dent Assoc* 1991;**122**:46–50.
- [7] Frentzen T, Koort HJ. Laser in dentistry: new possibilities with advancing laser technology technology. *Int Dent J* 1990;**40**:323–32.
- [8] Anneroth G, Ryden H, Zetterqvist L. The effect of low energy infra-red laser irradiation on wound healing in rats. *Brit J Oral Maxfac Surg* 1998;**26**:12–7.
- [9] Strang R, Moseley H, Carmichael A. Soft lasers-have they a place in dentistry? *Br Dent J* 1988;**165**:221–5.
- [10] Wakabayashi H, Hamba M, Matsumoto K, Tachibana H. Effect of irradiation by semiconductor laser on responses evoked in trigeminal caudal neurons by tooth pulp stimulation. *Lasers Surg Med* 1993;**13**: 605–10.
- [11] Paschoud Y, Holz J. Effect du soft-laser sur la néoformation d'un pont dentinaire après coiffage pulpaire direct de dents humaines à l'hydroxyde de calcium. I-étude histologique et au microscope électronique à balayage. *Rev Mens Suisse Odonto-Stomatol* 1988;**98**:345–56.
- [12] Murray PE, Smith AJ, Windsor LJ, Mjör IA. Remaining dentine thickness and human pulp response. *Int Endod J* 2003;**36**:33–43.
- [13] Mjör IA, Ferrari M. Pulp-dentine biology in restorative dentistry. Reactions to restorative materials, tooth-restoration interfaces, and adhesive techniques. *Quint Int* 2002;**33**:35–63.
- [14] Massa LF, Arana-Chavez VE. Ultrastructural preservation of rat embryonic dental tissues after rapid fixation and dehydration under microwave irradiation. *Eur J Oral Sci* 2000;**108**:74–7.
- [15] Utsunomiya T. A histopathological study of the effects of low-power laser irradiation on wound healing of exposed dental pulp tissues in dogs, with special reference to lectins and collagens. *J Endodont* 1998;**24**:187–93.
- [16] Accorinte ML, Loguercio AD, Reis A, Muench A, de Araujo VC. Response of human pulp capped with a bonding agent after bleeding control with hemostatic agents. *Oper Dent* 2005;**30**:147–55.
- [17] Kimura Y, Wilder-Smith P, Yonaga K, Matsumoto K. Treatment of dentine hypersensitivity by lasers: a review. *J Clin Periodontol* 2000;**27**:715–21.